

©2004, Acta Pharmacologica Sinica  
Chinese Pharmacological Society  
Shanghai Institute of Materia Medica  
Chinese Academy of Sciences  
<http://www.ChinaPhar.com>

# Total saponins of *Panax notoginseng* protected rabbit iliac artery against balloon endothelial denudation injury<sup>1</sup>

Si-wei CHEN, Xiao-hong LI<sup>2</sup>, Kai-he YE<sup>2</sup>, Zuo-feng JIANG, Xian-da REN<sup>2</sup>

*Department of Cardiology, the 4th Affiliated Hospital of Ji-nan University,*

*<sup>2</sup>Department of Clinical Pharmacology, Pharmacy College, Ji-nan University, Guangzhou 510632, China*

**KEY WORDS** *Panax ginseng*; saponins; balloon dilatation; restenosis; extracellular matrix; vascular smooth muscle

## ABSTRACT

**AIM:** To investigate whether total *Panax notoginseng* saponins (PNS) could protect endothelium of rabbit iliac artery against balloon endothelial denudation (BED) injury. **METHODS:** The morphology changes of the endothelium were observed with scanning electron microscope (SEM) and hematoxylin and eosin stain after BED of rabbit iliac artery at 0, 4, 6, and 8 week respectively. Vascular endothelial growth factor (VEGF) and matrix metalloproteinase-2 (MMP-2) was also determined by immunohistochemistry. PNS 10, 30, and 50 mg/kg were administered iv per day from 2 d before to 4 weeks after operation. **RESULTS:** The endothelium was denuded completely after BED. At the 4th week the endothelium was repaired in some degree, then recovered gradually at 6 and 8 week. The degree of intimal thickening at 4 week was significantly greater than that at 0, 6, or 8 week. The sequence of VEGF or MMP-2 staining from strong to weak was 4, 6, 0, 8 week, and normal control. However at 4 week, endothelial regeneration in PNS 30 and 50 mg/kg groups was significantly faster than that in saline group. The intimal thickness was significantly decreased and expressions of VEGF and MMP-2 were both down-regulated in PNS 30 or 50 mg/kg groups compared with saline control group. **CONCLUSION:** PNS promoted the endothelial regeneration and reduced ECM thickening, which was related to regulation of the expression of VEGF and MMP-2. PNS may have sustained antirestenotic effect after BED.

## INTRODUCTION

Restenosis after percutaneous transluminal coronary angioplasty (PTCA) is a frequent complication of this procedure<sup>[1]</sup>. It limits the long-term beneficial effects of PTCA. The use of stenter after balloon dilation has improved clinical prognosis in these patients, but late restenosis remains a relevant problem<sup>[2]</sup>. Preven-

tion of restenosis after successful PTCA remains one of the most challenging issues in the treatment of obstructive coronary artery disease. Restenosis after PTCA has a multifactorial etiology<sup>[3]</sup>. Extracellular matrix (ECM) accumulation induced vascular remodeling is an important reason<sup>[4]</sup>. The ECM can regulate the behaviour of vascular cells, including their ability to migrate, proliferate, and survive after injury<sup>[5]</sup>. Enhanced ECM accumulation rather than cell proliferation contributes to restenosis after PTCA. VEGF has been identified *in vitro* as a potent mitogen for endothelial cells in angiogenesis. The increase in VEGF mRNA expression after hypoxia induced by vascular injury can stimulate mature collagen synthesis. Meanwhile, hypoxia mi-

<sup>1</sup> Supported by Science Foundation of Guangdong Provincial Traditional Medicine Committee, No101038.

<sup>2</sup> Correspondence to Prof Xian-da REN. Phn 86-20-8522-0261. E-mail [tsam@jnu.edu.cn](mailto:tsam@jnu.edu.cn)

Received 2003-07-23

Accepted 2004-04-08

croenvironment decreases MMP-2 mRNA expression. Both caused deposition of ECM molecules early in wound repair<sup>[6]</sup>.

Total *Panax notoginseng* saponin (*PNS*), also known as sanchi ginseng, has been used in treating circulatory disorders among Chinese for hundreds of years. It is well documented that *PNS* exerts beneficial effects on the cardiovascular systems. It has been reported to be effective in treating cardiovascular diseases such as coronary thrombosis and in improving muscle microcirculation. *PNS* contains 24 dammarene type saponins (ginsenosides) including sanchinoside or notoginsenoside<sup>[7]</sup>. Other major compounds include flavonoids and amino acids<sup>[8]</sup>. Administration of the total saponins of *PNS* improved myocardial relaxation function<sup>[9]</sup>, lowered cerebrovascular resistance, suppressed proliferation of aortic smooth muscle cells induced by hypercholesterolemic serum, ameliorated cardiac function in the early stage postburn<sup>[10]</sup>, and enhanced fibrinolytic activity of bovine aortic endothelial cells<sup>[11]</sup>. Those effects indicated that *PNS* might be a valuable approach to the treatment of balloon-injured vessels. Therefore our preliminary study aimed to evaluate the effects of *PNS* on endothelial regeneration and ECM accumulation after balloon endothelium denudation (BED), and to explore the related mechanism(s).

## MATERIALS AND METHODS

**Materials** *PNS* was from Plant & Pharmaco Co Ltd (Yun-nan, China); mouse monoclonal antibodies against VEGF and MMP-2 were from Boshide Biotech Co (Wuhan, China). Other reagents were commercial products with analytic purity. Male New Zealand White rabbits weighing 2.6±0.2 kg were obtained from the Laboratory Animal Center of Guangzhou Traditional Chinese Medicine University (Certificate No 2001A067).

**Rabbit balloon injury** Rabbits were anesthetized with iv 0.6 % sodepent. A 2Fr Fogarty balloon catheter (Medtronic Limited, Minnesota, USA) was passed 15 cm proximal into the left external iliac artery through the femoral artery at a site proximal to its bifurcation for the descending genicular artery. The right external iliac artery was used as auto-control. The balloon was then inflated with air (3.5 kPa) and the catheter was pulled back three times to abrade the intimal surface to remove the endothelium. In a series of experiments, the complete removal of the endothelium using this procedure was confirmed by histological examination<sup>[12]</sup>. The iliac artery was subsequently ligated, and animals

were allowed to recover and kept on their normal diets.

**Experimental process** Firstly, 12 rabbits were randomly separated into four groups (3 in each group). They were sacrificed at 0, 4, 6, and 8 week after BED respectively.

Then, 16 rabbits were randomly divided into four groups (4 in each group). *PNS* 10, 30, and 50 mg/kg were injected by iv once a day from 2 days before BED. Saline was used as control. At 4 week after BED, the morphologic changes of the endothelium and expression of vascular endothelial growth factor (VEGF) and matrix metalloproteinase-2 (MMP-2) were determined.

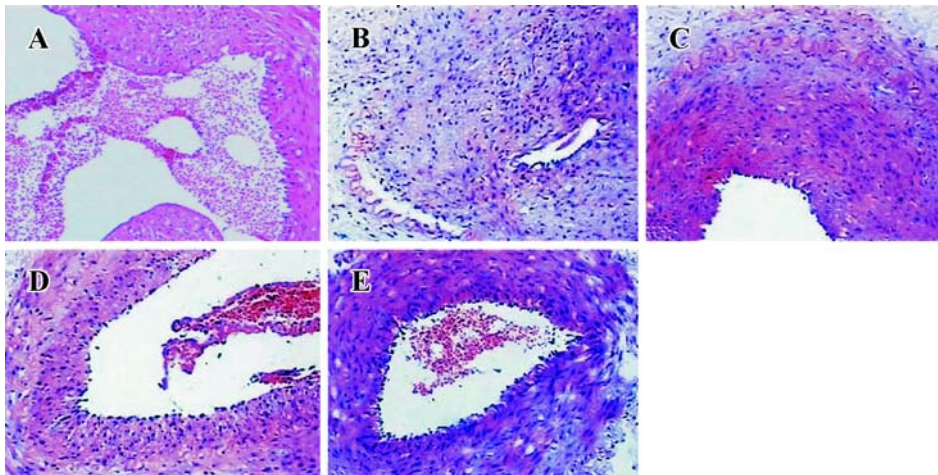
**Hematoxylin-eosin staining** The arteries were removed and fixed in 4 % paraformaldehyde for 2 h. After fixation, the arteries were cut into segments of 3-4 mm and embedded in paraffin. Serial cross-sections were stained with hematoxylin and eosin. Three cross-sections per artery were studied to evaluate ECM thickness.

**Scanning electron microscopy** Vessel samples were washed in cacodylate buffer, dissected in two halves, dehydrated in ascending concentrations of ethyl alcohol, and dried in CO<sub>2</sub> at the critical point. Then they were glued by a silver paste to aluminium stubs, coated with gold using argon, and observed with a scanning electron microscope (SEM) (Philip XL-30, Holland). Samples were studied under SEM for endothelial injury.

**Immunohistochemistry** The sections were deparaffined, boiled and retrieved in citric acid buffer for 10 min. Then, the immunohistochemical SABC method was used according to the specification of SABC kit (Bositer Biotech Co, Wuhan, China). The known positive sections were used as a positive control. Phosphate buffered solution (PBS) instead of the primary antibody was used as a negative control in each experiment.

## RESULTS

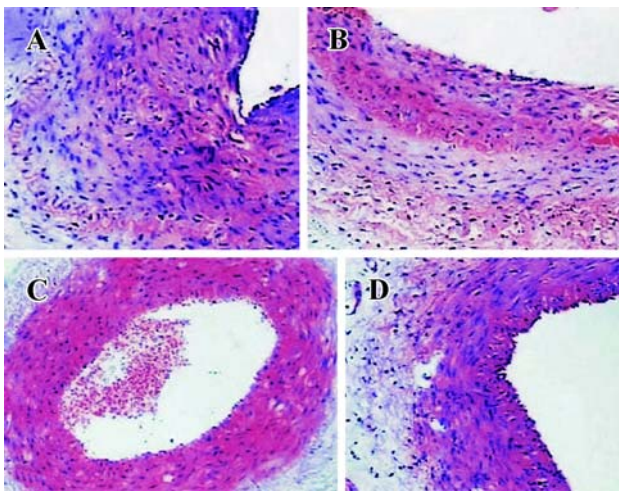
**HE stain** At 0 week, the intima of vessel was damaged and internal elastic lamina was exposed after BED (Fig 1A). However, the degree of intimal thickening was markedly greater at 4 week than that at 0 week, and the ECM accumulated greatly (Fig 1B). At 6 and 8 week, ECM accumulation was reduced gradually (Fig 1C, 1D). These suggested that 4 week after BED of rabbit iliac artery was the best stage to observe the protective effect of *PNS* on endothelium after BED. In *PNS* 30 or 50 mg/kg treated-groups ECM accumulation was greatly decreased but no change was observed in *PNS*



**Fig 1.** Morphologic changes of rabbit iliac artery after BED. A-D: 0, 4, 6, and 8 week after BED; E: normal control. HE stain.  $\times 33$ .

10 mg/kg group compared with saline control (Fig 2).

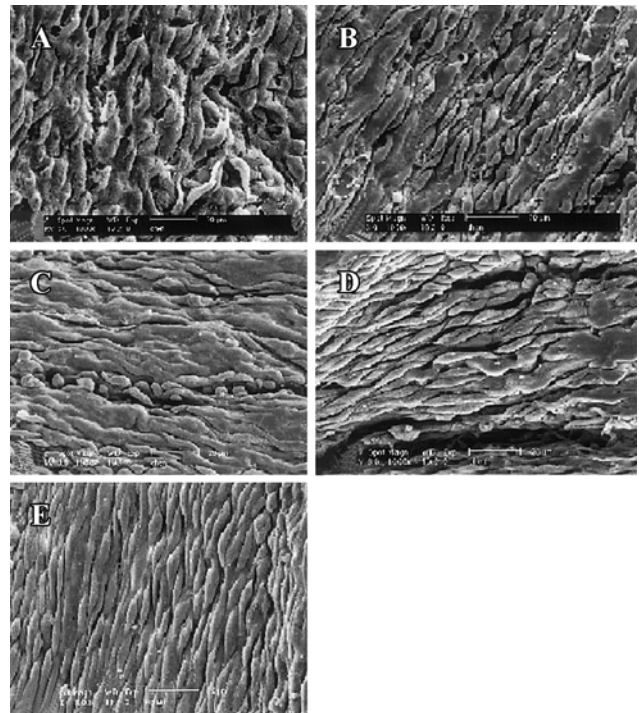
**Scanning electron microscopy** Endothelial cells were partially lost and basal lamina was damaged at 0 week after BED (Fig 3A). At 4 week, vascular endot-



**Fig 2.** Protective effect of PNS on rabbit iliac artery at 4 week after BED. A: saline group; B-D: PNS 10, 30, and 50 mg/kg. HE stain.  $\times 33$ .

helium were repaired to some degree. But the surface of endothelial cells remained distorted and intercellular space remained large (Fig 3B). From 6 to 8 week after BED, the intima was repaired significantly compared with that at 4 week but still had a little difference compared with saline control (Fig 3C, 3D). In saline control group endothelial cells showed normal fusiform with intact borders (Fig 3E).

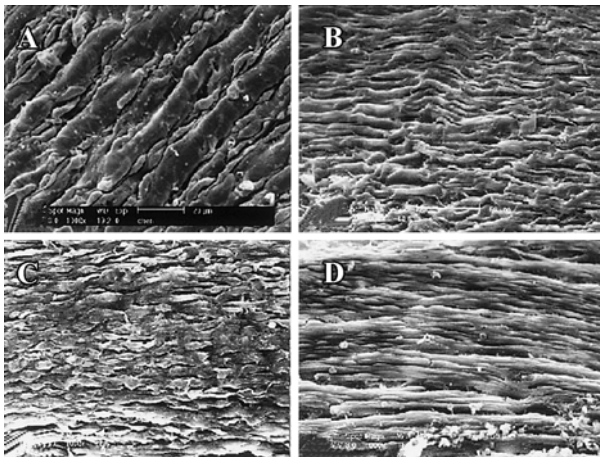
There was no apparent endothelial morphologic



**Fig 3.** Scanning electron micrograph of luminal surface of rabbit iliac artery after BED. A-D: 0, 4, 6, and 8 week after BED; E: normal control.  $\times 500$ .

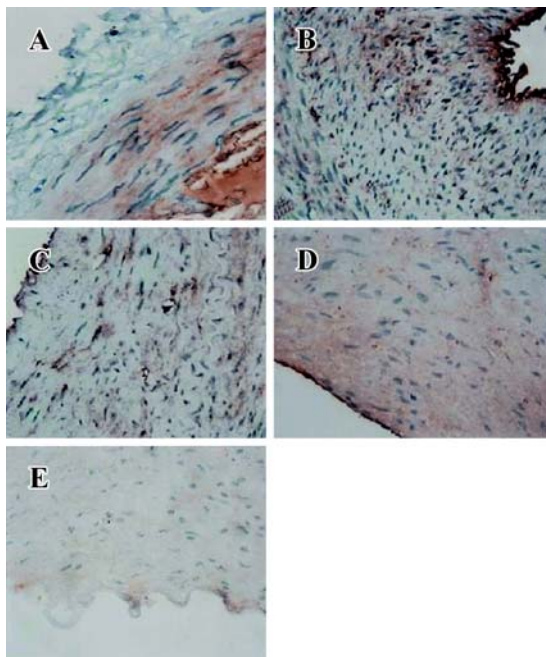
difference between saline group and PNS 10 mg/kg group (Fig 4A, 4B). In PNS 30 mg/kg group, endothelial cells with typical fusiform were lined up in order; but there were still some swelling endothelial cells (Fig 4C). In PNS 50 mg/kg group, the endothelial cells were regularly spaced and elongated. Almost no swelling endothelial cells could be observed (Fig 4D).



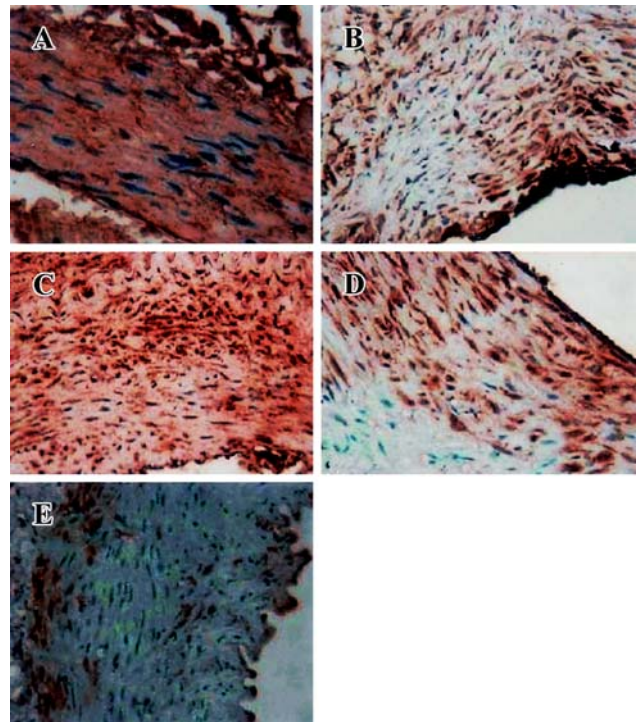


**Fig 4. Protective effect of PNS on rabbit iliac artery at 4 week after BED. A: saline group; B-D: PNS 10, 30, and 50 mg/kg. ×500.**

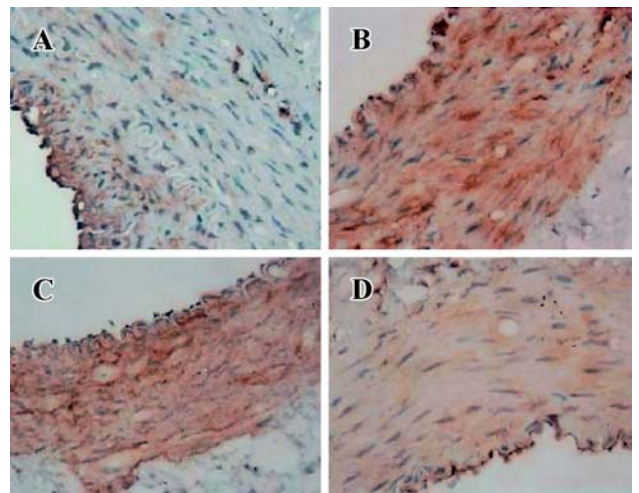
**Expression of VEGF and MMP-2 proteins** At 0, 4, and 6 week, expression of VEGF and MMP-2 were higher than that in saline control group. But they became weak at 8 week. The sequence of VEGF or MMP-2 staining from strong to weak was 4, 6, 0, and 8 week (Fig 5, 6). However, in PNS-treated groups, the expression of VEGF and MMP-2 was decreased. But expression of VEGF and MMP-2 in PNS 10 mg/kg group was higher than that in PNS 30 and 50 mg/kg group (Fig 7, 8).



**Fig 5. VEGF expression of rabbit iliac artery after BED. A-D: 0, 4, 6, and 8 week after BED; E: normal control. ×200.**



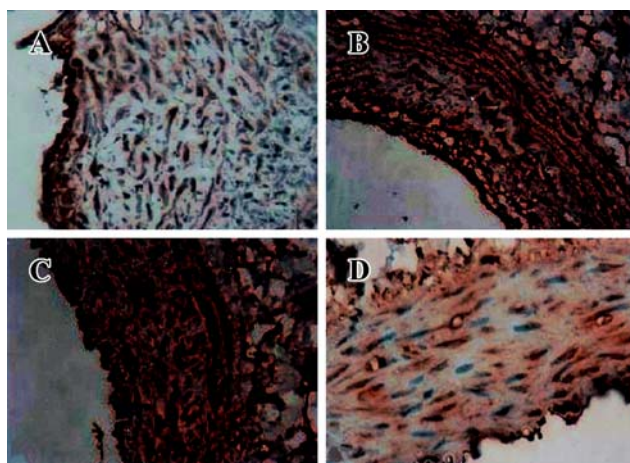
**Fig 6. MMP-2 expression of of rabbit iliac artery after BED. A-D: 0, 4, 6, 8 week after BED; E: normal control. ×200.**



**Fig 7. Effect of PNS on VEGF expression of of rabbit iliac artery at 4 week after BED. A: saline group; B-D: PNS 10, 30, and 50 mg/kg. ×200.**

**DISCUSSION**

In this study we observed less intima thickening and accelerated repair of endothelium in PNS 30 and 50 mg/kg groups indicating that PNS had beneficial effects on endothelium after BED. Expressions of VEGF



**Fig 8. Effect of PNS on MMP-2 expression of rabbit iliac artery at 4 week after BED. A: saline group; B-D: PNS 10, 30, and 50 mg/kg.  $\times 200$ .**

and MMP-2 in PNS treated-groups were down-regulated.

Growth factors are potent SMC mitogens as they are involved in ECM synthesis<sup>[13]</sup>. VEGF is one of the best-studied and characterized inducers of angiogenesis. Augmentation of VEGF stimulates endothelial regeneration, helps maintaining endothelial integrity, and enhances eNOS expression and endothelial NO production<sup>[14]</sup>. VEGF is increased from primary lesions to prevent restenosis after PTCA, suggesting a possible role in the process of angiogenesis through the recruitment and proliferation of endothelial cells<sup>[15]</sup>. We found that expression of VEGF increased at 0 week after BED and continued to be strong and persistent even at 6 week, but decreased at 8 week suggesting its important role in endothelium repair. Not only was VEGF important during the initial stages of endothelium repair but also it played a crucial role in the subsequent maturation and maintenance of the new vascularization<sup>[16]</sup>. The decreased expression of VEGF at 8 week may be due to the repairment of endothelium. It is the feedback of decreased stimulation of injury. The expression of VEGF from strong to weak reflected the repairing process of endothelium. So why VEGF expression in PNS 30 or 50 mg/kg groups was weaker than that in PNS 10 mg/kg group and saline groups could be explained.

Previous studies showed that VEGF stimulated endothelial MMP-2 and MMP-9 release in a concentration- and time-dependent (6-24 h) manner<sup>[17]</sup> and expression of MMP-2 was correlated to VEGF in patients with renal cell carcinoma<sup>[18]</sup>. Increase in VEGF accom-

panied with increase in MMP-2 in this study was in agreement with the above reports.

The remodeling of basement membrane is especially involved in MMP-2. MMP-2 can degrade gelatin, several kinds of collagens, and components of vascular basement membrane, hence it can affect the remodeling of vascular ECM<sup>[19]</sup>. We found that expression of MMP-2 was lower at 8 week than that at 0 week after BED and lower in PNS 30 and 50 mg/kg group than that in PNS 10 mg/kg group and saline control group. It could be explained that increase in MMP-2 in stress conditions represents a compensatory mechanism against the excessive accumulation of ECM. Less MMP-2 expression in PNS 30 or 50 mg/kg group may be due to less ECM deposition after endothelium repairment.

In summary PNS promoted endothelial regeneration, reduced ECM deposition, and down-regulated VEGF and MMP-2 expression of rabbit iliac arteries after BED.

## REFERENCES

- 1 Nash IS. Improving of percutaneous coronary intervention. *Am Heart J* 1999; 136: 979-82.
- 2 Dietz U, Rupprecht HJ, de Belder MA, Wijns W, Quarles van Ufford MA, Klues HG, *et al*. Angiographic analysis of the angioplasty versus rotational atherectomy for the treatment of diffuse in-stent restenosis trial (ARTIST). *Am J Cardiol* 2002; 90: 843-7.
- 3 Beygui F, Feuvre CL, Maunoury C, Helft G, Antonietti T, Metzger JP, *et al*. Detection of coronary restenosis by exercise electrocardiography thallium-201 perfusion imaging and coronary angiography in asymptomatic patients after percutaneous transluminal coronary angioplasty. *Am J Cardiol* 2000; 86: 35-40.
- 4 Horlitz M, Sigwart U, Niebauer J. Fighting restenosis after coronary angioplasty: contemporary and future treatment options. *Int J Cardiol* 2002; 83: 199-205.
- 5 Raines, Elaine W. The extracellular matrix can regulate vascular cell migration, proliferation, and survival: relationships to vascular disease. *Int J Exp Pathol* 2000; 81: 73-83.
- 6 Steinbrech DS, Longaker MT, Mehrara BJ, Saadeh PB, Chin GS, Gerrets RP, *et al*. Fibroblast response to hypoxia: the relationship between angiogenesis and matrix regulation. *J Surg Res* 1999; 84: 127-33.
- 7 Ma WG, Mizutania M, Malterud KE. Saponins from the roots of *Panax notoginseng*. *Phytochemistry* 1999; 52: 1133-9.
- 8 Lam SK, Ng TB. Isolation of a small chitinase-like antifungal protein from *Panax notoginseng* (sanchi ginseng) roots. *Int J Biochem Cell Biol* 2001; 33: 287-92.
- 9 Chan P, Thomas GN, Tomlinson B. Protective effects of trillinolein extracted from *Panax notoginseng* against cardio-

- vascular disease. *Acta Pharmacol Sin* 2002; 23: 1157-62.
- 10 Huang YS, Yang ZC, Yan BG, Hu XC, Li AN, Crowther RS. Improvement of early postburn cardiac function by use of *Panax notoginseng* and immediate total eschar excision in one operation. *Burns* 1999; 25: 35-41.
  - 11 Liu JW, Wei DZ, Du CB, Zhong JJ. Enhancement of fibrinolytic activity of bovine aortic endothelial cells by ginsenoside Rb<sub>2</sub>. *Acta Pharmacol Sin* 2003; 24: 102-8.
  - 12 Inoue K, Cynshi O, Kawabe Y, Nakamura M, Miyauchi K, Kimura T, *et al*. Effect of BO-653 and probucol on c-MYC and PDGF-A messenger RNA of the iliac artery after balloon denudation in cholesterol-fed rabbits. *Atherosclerosis* 2002; 161: 353-63.
  - 13 Hilker M, Buerke M, Guckenbiehl M, Schwertz H, Buhler J, Moersig W, *et al*. Rapamycin reduces neointima formation during vascular injury. *Vasa* 2003; 32: 10-3
  - 14 Laitinen M, Zachary I, Breier G, Pakkanen T, Hakkinen T, Luoma J, *et al*. VEGF gene transfer reduces intimal thickening via increased production of nitric oxide in carotid arteries. *Hum Gene Ther* 1997; 8: 1737-44.
  - 15 Lelkes PI, Hahn KA, Karmioli S. Hypoxia/reoxygenation enhances tube formation of cultured human microvascular endothelial cells: the role of reactive oxygen species. In: Maragoudakis ME, editor. *Angiogenesis: models, modulators, and clinical applications*. New York: Plenum Press; 1998. p321-36.
  - 16 Nilanjana M, Dipak KD. Redox signaling in vascular angiogenesis. *Free Radic Biol Med* 2002; 33: 1047-60.
  - 17 Narumiya H, Zhang Y, Fernandez-Patron C, Guilbert LJ, Davidge ST. Matrix metalloproteinase-2 is elevated in the plasma of women with preeclampsia. *Hypertens Pregnancy* 2001; 20: 185-95.
  - 18 Zhang XH, Yamashita M, Uetsuki H, Kakehi Y. Angiogenesis in renal cell carcinoma: Evaluation of microvessel density, vascular endothelial growth factor and matrix metalloproteinases. *Int J Urol* 2002; 9: 509-15.
  - 19 Rossella B, Luigi R, Rita R. Cyclosporine A up-regulates expression of matrix metalloproteinase 2 and vascular endothelial growth factor in rat heart. *Int Immunopharmacol* 2003; 3: 427-33.